



DATE PRESENTING CLINICAL SIGNS

11.24.25

PATIENT

Ollie Brandt

SPECIES

Feline

BREED

DSH

SEX

MN

AGE

11.11.21

WEIGHT

10.1lbs

INTERPRETED BY

Maggie Machen Lamy,
DVM, DACVIM
(Cardiology)

HOSPITAL NAME

Mason Dixon Animal
ER

REFERRING VET

Dr. Bateman

History: Presented on 11/22/25 for a sudden onset of labored breathing a few hours after a medicated mousse was applied to his haircoat. He was oxygen dependent on presentation, and he was started on treatments for CHF. History of ringworm. hx of UO and had PU sx ~1 year ago
-Pertinent abnormal PE/Chem/CBC/UA Results: ProBNP normal at < 50. CBC: wnl. CHEM 6/lytes: BG 256.Pcv/ts: 50/8.0.

-CXR: 1. Pulmonary pattern: in combination with the mildly distended cranial pulmonary vessels, cardiogenic pulmonary edema is possible, but (aspiration) pneumonia, allergic reaction, other type of non-cardiogenic edema or hemorrhage could be considered as well.

-Current medications: None listed.

-Sedation used: Not required to complete full diagnostic ultrasound.

-Pertinent previous ultrasound results: No previous.

-STAT: Requested.

-Imaging performed by: Stephanie Warg RDCS, RVT.

ECHOCARDIOGRAM FINDINGS

2D, m-mode, color flow and doppler imaging is available. The LV chamber is decreased with normal wall thickness. The endocardium is hyperechoic. The papillary muscles are normal in size and hyperechoic. The left atrium is normal in size. The right atrium is normal in size. The right ventricle appears normal. The mitral valve is normal in structure and mobility. No obvious valve regurgitation. Blood flow through both the LVOT and RVOT is normal in velocity. No pleural or pericardial effusion seen. No obvious cardiac tumors.

CARDIAC CHART

FELINE CARDIAC PARAMETERS	BODY WEIGHT (kg)	HR (BPM)	IVSd (cm) (Moise, Pipers)	LVIDd (cm) (Moise, Pipers)	LVWd (cm) (Moise, Pipers)	FS (%)	EF (%)
NORMAL PARAMETER	-----	150-240	3.5-0.55	<2 (mean 1.5)	3.5-0.55	35-67	80-100
PATIENT	4.6	NM	0.45	0.9	0.46	48	83
FELINE CARDIAC PARAMETERS	LA/AO (Boon)	LA/AO HEART BASE (Swe) (Abbott)	LA 2D short axis Base view (cm) (Abbott)		LVOT VEL (m/s)	RVOT VEL (m/s)	E max (m/s)
NORMAL	<1.5	<1.3	<1.2		<1.6	<1.3	<0.9
PATIENT	NM	1.2	1.1		1.0	1.6	NM

Adapted from June Boon, Veterinary Echocardiography,1998
Abbott J & MacLean H JVIM 2006;20: 111-119, Moise et al. Am J Vet Res 47:1476, 1986. Pipers et al. Am J Vet Res 40:882, 1979.

INVOICE

45904

INTERPRETATION OF THE FINDINGS & FURTHER RECOMMENDATIONS

Overtly normal cardiac structure and function. The LV chamber is decreased, which is most consistent with volume depletion secondary to diuretics. No LV hypertrophy is seen, and the LA dimension is normal suggesting low risk for complication. Flow through the great vessels is normal, and no significant valve regurgitation is identified.

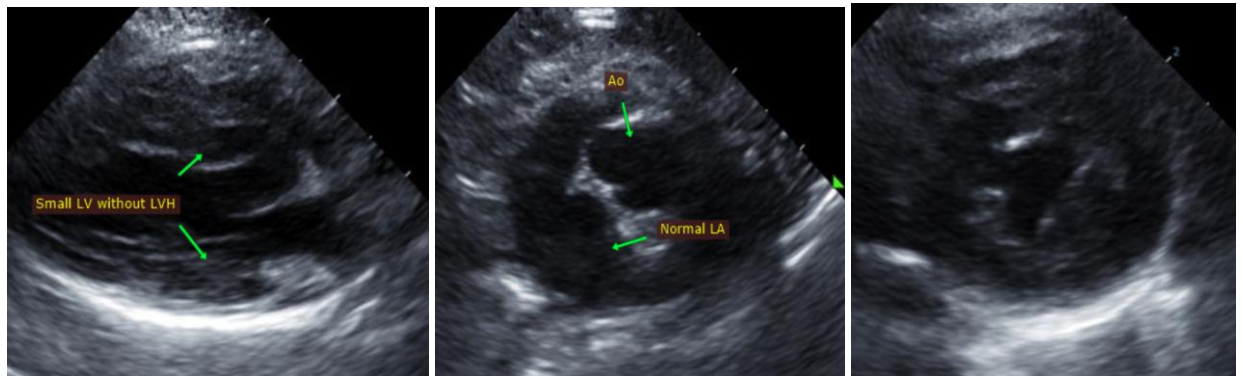
These findings would suggest that CHF is ruled out in this case, which is supported by a normal BNP value. Lasix should be discontinued and consider cautious fluid therapy if clinically indicated. Further workup for respiratory issues is recommended.

Given these findings, no medications are indicated. Prognosis is good.

Anesthetic risk is considered mild. Risk for complication with steroid use or fluid administration typically follows LA dilation, which in this case is low. That being said, any cat can experience unexpected signs of intolerance and monitoring of RR/RE is advised particularly in the initiation phase.

Recommend recheck echocardiogram in 1 year to assess for any progressive issues.

IMAGES



The information and recommendations provided are based on the images presented by the referring veterinarian. No evaluation can be communicated regarding pathology that was not visible in the image/video clips provided.

Thank you for this referral. This report was generated using transcription software, and minor dictation errors may be present. If the clinical or image interpretation does not parallel your findings or if I can be of any further assistance, please contact me.

Maggie Machen Lamy, DVM
Diplomate of the American College of Veterinary Internal Medicine (Cardiology)
info@sonopath.com